




OPEN ACCESS

Sulperazon-induced acute reactive thrombocytopenia during treatment of systemic lupus erythematosus: a case report

Mengen Lv ,^{1,2} Qing Xu,^{1,2} Xianfei Ye,^{1,2} Qian Yu^{1,2}

¹Department of Laboratory Medicine, the First Affiliated Hospital, Zhejiang University School of Medicine, Hangzhou, China

²Key Laboratory of Clinical In Vitro Diagnostic Techniques of Zhejiang Province, Hangzhou, People's Republic of China

Correspondence to

Dr Mengen Lv, Department of Laboratory Medicine, the First Affiliated Hospital, Zhejiang University School of Medicine, Hangzhou, Zhejiang, China; zyylme@zju.edu.cn

Received 2 August 2021

Accepted 24 August 2021

Published Online First 8 September 2021

SUMMARY

The purpose of this study is to report a patient who developed acute reactive thrombocytopenia while undergoing treatment with sulperazon for systemic lupus erythematosus (SLE). Sulperazon is a broad-spectrum antibiotic that can act against a wide range of microorganisms, but rarely causes severe thrombocytopenic events. We describe a 62-year-old man with new-onset acute reactive thrombocytopenia who experienced a precipitous fall in the platelet count from $168 \times 10^9/L$ to $1 \times 10^9/L$ within 29 hours after exposure to sulperazon. Sulperazon was immediately discontinued followed by administration of intravenous immunoglobulin for six consecutive days. The platelet count eventually recovered and petechiae at the injection sites improved. No complications secondary to acute reactive thrombocytopenia were observed except petechiae.

BACKGROUND

Patients with systemic lupus erythematosus (SLE) are usually treated with a combination of systemic corticosteroids and immunosuppressive agents, which can lead to an increased risk of secondary infections. In clinical practice, antibiotics are commonly used to treat patients with SLE with secondary infections, but their efficacy and safety have to be given serious consideration. The side effects of antibiotics have been shown to be a significant issue for patients because some adverse events can have serious consequences and even be life-threatening.¹ Therefore, it is necessary to recognise and carefully monitor the side effects of antibiotic treatment.

Sulperazon, a 2:1 combination of the beta-lactam antibiotic cefoperazone and the irreversible beta-lactamase inhibitor sulbactam, is a broad-spectrum antibiotic that is commonly used to treat infections in hospitalised patients.² Although it is well tolerated, the side effects still cannot be ignored. In addition to common side effects such as diarrhoea and rash, transient thrombocytopenia has been reported as a rare side effect.^{3,4} Clinicians involved in the management of patients should be aware of undesirable side effects of sulperazon, and prompt recognition is key to appropriate management.

We present a rare case of confirmed sulperazon-induced acute reactive thrombocytopenia after initiation of empirical treatment for SLE. It occurred within 29 hours after exposure to sulperazon with a precipitous fall in the platelet count from $168 \times 10^9/L$ to $1 \times 10^9/L$, and was completely

reversed after sulperazon withdrawal and intravenous immunoglobulin administration for 6 days. To the best of our knowledge, no previous studies have reported sulperazon-induced acute reactive thrombocytopenia in patients with SLE.

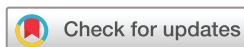CASE PRESENTATION

A 62-year-old man was admitted to our hospital with a 1-month history of cervicodorsal pain and fever for 3 days. He was not taking any immunosuppressive agents and denied a family history of immune system disorders. There was no history of blood transfusion or drug allergy. He was diagnosed with active SLE based on the clinical symptoms, laboratory results (table 1) and SLE disease activity index (score of 15 points).

At admission his baseline platelet count was $181 \times 10^9/L$ (range $83\text{--}303 \times 10^9/L$). On day 1, hydroxychloroquine sulfate 400 mg/day and corticosteroid 40 mg/day were initiated. Meanwhile, the patient was started on low molecular weight heparin (enoxaparin, 8000 U/day) to prevent deep vein thrombosis. After 2 days of treatment, the patient's cervicodorsal pain and fever completely disappeared without recurrence. His pulmonary CT revealed the presence of a pleural effusion due to lung infection, so sulperazon 4 g/day was administered at 11:25 hours on day 3. However, the result of a routine blood examination at 16:30 hours on day 4 showed acute reactive thrombocytopenia. Unexpectedly, the platelet count in the peripheral circulation decreased dramatically from an initial level of $168 \times 10^9/L$ to $1 \times 10^9/L$ within 29 hours (figure 1). Meanwhile, the patient developed symptoms of drowsiness and petechiae at the injection sites, which did not significantly improve until day 7.

INVESTIGATIONS

At that point, thrombotic thrombocytopenic purpura, heparin- or drug-induced thrombocytopenia were suspected. Emergency ultrasonography showed that the deep venous blood flow of both lower limbs was unobstructed. The levels of D-dimer and lactic dehydrogenase were $5022 \mu\text{g}/\text{FEU}$ and $229 \text{U}/\text{L}$, respectively, and the plasma levels of anti-ADAMTS13 IgG antibodies were negative. Other laboratory data including red blood cell count, haemoglobin and indirect bilirubin remained stable compared with those at admission (table 1). Moreover, the 4Ts score was low at only 2 points according to the widely used 4Ts scoring system for heparin-induced thrombocytopenia. On



© European Association of Hospital Pharmacists 2023. Re-use permitted under CC BY-NC. No commercial re-use. Published by BMJ.

To cite: Lv M, Xu Q, Ye X, et al. *Eur J Hosp Pharm* 2023;**30**:e18.

Case report

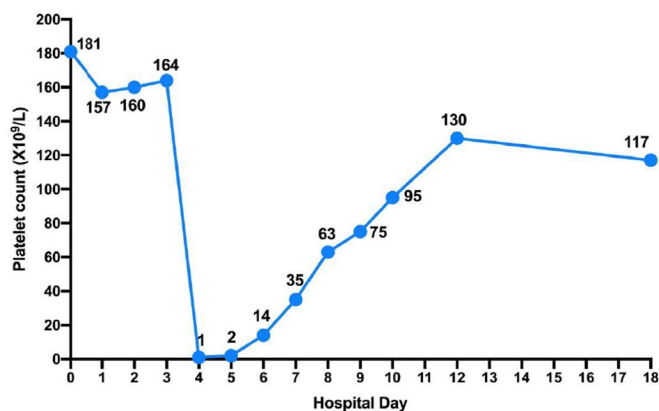
Table 1 Laboratory results on admission and within 24 hours after the onset of acute reactive thrombocytopenia

Laboratory indicators	Value		Reference value/judgement criteria
	On admission	Within 24 hours after onset of acute reactive thrombocytopenia	
White blood cell count, $\times 10^9/L$	5.20	4.30	4.0–10.0
Lymphocyte count, $\times 10^9/L$	0.44	0.25	0.8–4.0
Red blood cell count, $\times 10^{12}/L$	3.46	3.15	4.09–5.74
Haemoglobin, g/L	104	94	131–172
Lactic dehydrogenase, U/L	230	229	120–250
Total bilirubin, $\mu\text{mol}/L$	3.5	4.6	0.0–26.0
Indirect bilirubin, $\mu\text{mol}/L$	1.7	2.4	3.0–14.0
Creatinine, $\mu\text{mol}/L$	85	67	59–104
Urea, mmol/L	5.99	5.27	2.90–8.20
Uric acid, $\mu\text{mol}/L$	369	261	208–428
Platelet count, $\times 10^9/L$	181	2	83–303
D-dimer, $\mu\text{g}/\text{FEU}$	31 814	5022	0–700
Activated partial thromboplastin time, s	26.9	29.6	23.9–33.5
Anti-nuclear antibody	1:320	–	1:20
Anti-double-stranded DNA	Positive	–	Negative
Anti-nuclear antibody	Positive	–	Negative
Anti-extractable nuclear antigen antibodies	Positive	–	Negative
Anti-ADAMTS13 IgG	–	Negative	Negative

further questioning of his previous medication history, we found that the patient had used ceftriaxone 8 days prior to admission.

TREATMENT

Given the side effect of thrombocytopenia associated with both sulperazon and enoxaparin, they were discontinued immediately on day 4. Subsequently, intravenous immunoglobulin at a dose of 25 g/day for six consecutive days was started on day 4. Over the ensuing days, the patient received piperacillin/tazobactam 13.5 g/day on day 7, followed by a combination of the anticoagulant rivaroxaban 10 mg/day on day 10 as an alternative treatment.

**Figure 1** Trajectory of the platelet count during the hospital stay.

OUTCOME AND FOLLOW-UP

After adjustment of medication regimens, these were well tolerated with no recurrence of acute thrombocytopenia episodes. The patient was discharged 18 days after illness onset in good clinical condition, with improved petechiae at the injection sites.

The coagulation profile and platelet count of the patient were within normal limits and the petechiae disappeared during a 1-month follow-up period.

DISCUSSION

The aetiology of thrombocytopenia in hospitalised patients is heterogeneous and commonly includes infections, thrombotic thrombocytopenic purpura (TTP), disseminated intravascular coagulation, heparin and drugs such as antibiotics.⁵ Thrombocytopenia is also a common clinical manifestation in patients with SLE.⁶ Zhan *et al* reported that SLE-associated thrombocytopenia had a median platelet count of $66 \times 10^9/L$ with a range of $29\text{--}95 \times 10^9/L$.⁷ Accordingly, the causes of acute reactive thrombocytopenia were highly suspected other than SLE itself. In our case the underlying causes were TTP, heparin or drug reactions.

TTP is a rare and potentially lethal thrombotic microangiopathy typically characterised by thrombocytopenia, microangiopathic haemolytic anaemia, neurological abnormalities and a severe deficiency or reduction of ADAMTS13 activity (less than 10%).⁸ Despite its rare occurrence, the association of TTP and SLE has been described in the literature.⁹ Our patient had a normal baseline platelet count on admission and remained stable during the first 2 days of treatment, but acute thrombocytopenia occurred unexpectedly on day 4 with a minimum platelet count of $1 \times 10^9/L$. Compared with the corresponding results on admission, the platelet count and D-dimer level decreased more significantly within 24 hours after the onset of acute reactive thrombocytopenia (table 1). However, there were no significant changes in the red blood cell count, haemoglobin, lactic dehydrogenase and indirect bilirubin levels. The clinical symptoms were dominated by drowsiness and petechiae at the injection sites. In addition, the results of anti-ADAMTS13 IgG and ultrasonography did not support the diagnosis of TTP. Therefore, TTP-induced thrombocytopenia was ruled out first.

The cause of thrombocytopenia was then assessed according to the type of medication or duration of medication, and heparin- or drug-induced reactive thrombocytopenia was speculated to be the most likely cause. As enoxaparin and sulperazon both have the side effects of thrombocytopenia, we recommended the clinicians withdraw them immediately. The patient was treated with intravenous infusions of immunoglobulin 25 g daily for 6 days and the platelet count gradually returned to the normal range.

Enoxaparin is a low-molecular weight heparin that has a lower incidence of heparin-induced thrombocytopenia (HIT).¹⁰ Currently, HIT is not a plausible diagnosis for our patient due to the following reasons: (a) the onset of thrombocytopenia began only 4 days after starting enoxaparin, but HIT is a moderate thrombocytopenia that starts at least 5–10 days after heparin administration, too soon to be explained by heparin-induced immunisation; (b) HIT is not characterised by such severe thrombocytopenia and the platelet count is rarely less than $20 \times 10^9/L$,¹¹ but our patient's platelet count fell to $1 \times 10^9/L$; and (c) according to the widely used 4Ts scoring system, the total score of our patient was only 2, which had a very high negative predictive value of 97–99% for HIT.¹² Therefore, HIT was largely excluded.

Thus, sulperazon was the most likely cause. Typically, drug-induced immune thrombocytopenia (DITP) occurs in one to several weeks following drug exposure.¹³ DITP, which refers only to immune-mediated platelet destruction rather than myelosuppression, is characterised by severe thrombocytopenia and is often misdiagnosed as idiopathic thrombocytopenic purpura. Its incidence is unknown as well as it is not fully recognised by clinicians.¹⁴ Antibodies only react with platelets in the presence of the sensitising drug, antibody drug/platelet interactions may result in severe thrombocytopenia.¹⁵ In the present case, the reactive thrombocytopenia showed a temporal relationship with sulperazon administration. When sulperazon was discontinued for 6 days, the platelet levels were reversed. However, the acute thrombocytopenia of our patient initially occurred within 29 hours of exposure to sulperazon, implying that drug-induced antibodies may have been present in vivo before exposure. Once the sensitising drug was withdrawn, the binding affinities of these antibodies were too low to cause severe thrombocytopenia. Further inquiry about the patient's medication history revealed that he had used ceftriaxone 8 days before admission. Evidence already exists that ceftriaxone can induce immune-mediated thrombocytopenia.¹³ Since both belong to the third-generation cephalosporins, cross-reactivity has also been described between cefoperazone and ceftriaxone antibodies.¹⁶ We therefore suggest that pre-existing cross-reactive antibodies to sulperazon may be responsible for this rapid onset of thrombocytopenia. The exact pathogenesis of immune thrombocytopenia induced by beta-lactam drugs is not fully understood. Studies have suggested that it is mediated by IgG and IgM immunoglobulins that recognise membrane glycoproteins expressed on platelets, ultimately activating the complement system and promoting platelet destruction.¹⁷ Although DITP has a mild clinical course in most cases, the fact that in this case it was severe may be due to cross-reaction between cefoperazone and ceftriaxone. This cross-reaction can be explained by the reaction of side chains shared by several different beta-lactam drugs with the patient's antibody, resulting in the specificity of the platelet glycoprotein target.¹⁸

Based on these facts, we conclude that the self-limited acute reactive thrombocytopenia was most likely induced by sulperazon. Because sulperazon is well tolerated by most patients, a rapid decrease in the platelet count in a short time may be related to individual factors. One limitation of this report is the absence of any further experimental methods for detecting drug-induced antibodies. Regardless of this, the present case highlights that DITP must be considered in the setting of unexplained thrombocytopenia.

Learning points

- ⇒ When sulperazon is used, the patient's platelet count should be monitored routinely.
- ⇒ Drug-induced immune thrombocytopenia should be highly suspected in any patient with unexplained acute thrombocytopenia, as early interventions will lead to improved outcome.
- ⇒ This case report illustrates the importance of multidisciplinary collaboration in recognising and treating drug reaction.

Contributors All authors contributed to the article. ML wrote the manuscript. QY collected and analysed the laboratory results and medical history of the patient. QX and XY revised and edited the manuscript. All authors have read and approved the final manuscript.

Funding The authors have not declared a specific grant for this research from any funding agency in the public, commercial or not-for-profit sectors.

Competing interests None declared.

Patient consent for publication Obtained.

Provenance and peer review Not commissioned; internally peer reviewed.

Data availability statement All data relevant to the study are included in the article.

Open access This is an open access article distributed in accordance with the Creative Commons Attribution Non Commercial (CC BY-NC 4.0) license, which permits others to distribute, remix, adapt, build upon this work non-commercially, and license their derivative works on different terms, provided the original work is properly cited, an indication of whether changes were made, and the use is non-commercial. See: <http://creativecommons.org/licenses/by-nc/4.0/>.

ORCID iD

Mengen Lv <http://orcid.org/0000-0003-0439-3430>

REFERENCES

- 1 Mohsen S, Dickinson JA, Somayaji R. Update on the adverse effects of antimicrobial therapies in community practice. *Can Fam Physician* 2020;66:651–9.
- 2 Xin X, Jian L, Xia X, et al. A multicentre clinical study on the injection of ceftriaxone/sulbactam compared with cefoperazone/sulbactam in the treatment of respiratory and urinary tract infections. *Ann Clin Microbiol Antimicrob* 2013;12:38–8.
- 3 Bodey GP, Elting LS, Narro J, et al. An open trial of cefoperazone plus sulbactam for the treatment of fever in cancer patients. *J Antimicrob Chemother* 1993;32:141–52.
- 4 Suzuki K, Horiba M. [Laboratory and clinical study of sulbactam/cefoperazone (SBT/CPZ) on bacterial prostatitis]. *Hinyokika Kyo* 1991;37:1333–43.
- 5 Zitella LJ. Approach to the hospitalized patient with thrombocytopenia. *J Adv Pract Oncol* 2021;12:267–70.
- 6 Ziakas PD, Giannouli S, Zintzaras E, et al. Lupus thrombocytopenia: clinical implications and prognostic significance. *Ann Rheum Dis* 2005;64:1366–9.
- 7 Zhan Y, Cheng L, Wu B, et al. Interleukin (IL)-1 family cytokines could differentiate primary immune thrombocytopenia from systemic lupus erythematosus-associated thrombocytopenia. *Ann Transl Med* 2021;9:222.
- 8 Joly BS, Coppo P, Veyradier A. Thrombotic thrombocytopenic purpura. *Blood* 2017;129:2836–46.
- 9 Jiang H, An X, Li Y, et al. Clinical features and prognostic factors of thrombotic thrombocytopenic purpura associated with systemic lupus erythematosus: a literature review of 105 cases from 1999 to 2011. *Clin Rheumatol* 2014;33:419–27.
- 10 Saheb Sharif-Askari F, Syed Sulaiman SA, Saheb Sharif-Askari N, et al. Adverse outcomes of anticoagulant use among hospitalized patients with chronic kidney disease: a comparison of the rates of major bleeding events between unfractionated heparin and enoxaparin. *PLoS One* 2014;9:e106517.
- 11 Greinacher A. Heparin-Induced thrombocytopenia. *N Engl J Med Overseas Ed* 2015;373:252–61.
- 12 Lo GK, Juhl D, Warkentin TE, et al. Evaluation of pretest clinical score (4T's) for the diagnosis of heparin-induced thrombocytopenia in two clinical settings. *J Thromb Haemost* 2006;4:759–65.
- 13 Ali N, Auerbach HE. New-onset acute thrombocytopenia in hospitalized patients: pathophysiology and diagnostic approach. *J Community Hosp Intern Med Perspect* 2017;7:157–67.
- 14 Vayne C, Guéry E-A, Rollin J, et al. Pathophysiology and diagnosis of drug-induced immune thrombocytopenia. *J Clin Med* 2020;9:2212.
- 15 Danese E, Montagnana M, Favalaro EJ, et al. Drug-Induced thrombocytopenia: mechanisms and laboratory diagnostics. *Semin Thromb Hemost* 2020;46:264–74.
- 16 Arndt PA, Garratty G. Cross-reactivity of cefotetan and ceftriaxone antibodies, associated with hemolytic anemia, with other: cephalosporins and penicillin. *Am J Clin Pathol* 2002;118:256–62.
- 17 Aster RH, Bougie DW. Drug-induced immune thrombocytopenia. *N Engl J Med* 2007;357:580–7.
- 18 Slaughter M, Rasmussen M, Bougie D, et al. Immune thrombocytopenia induced by beta-lactam antibiotics: cross-reactions of responsible antibodies with other beta-lactam drugs. *Transfusion* 2021;61:1600–8.